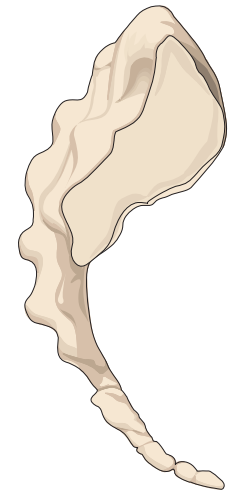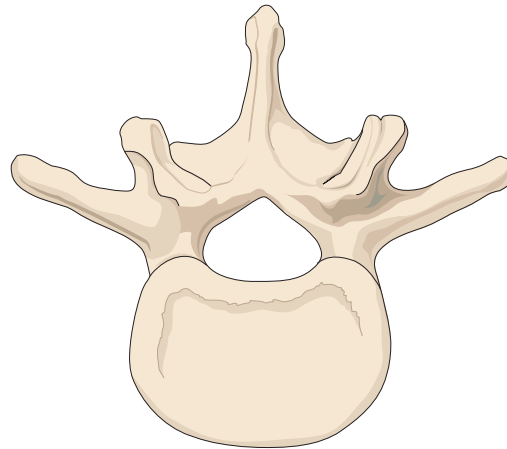
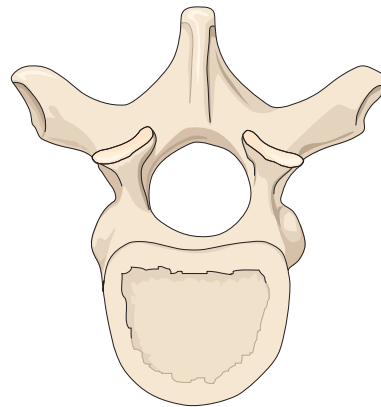
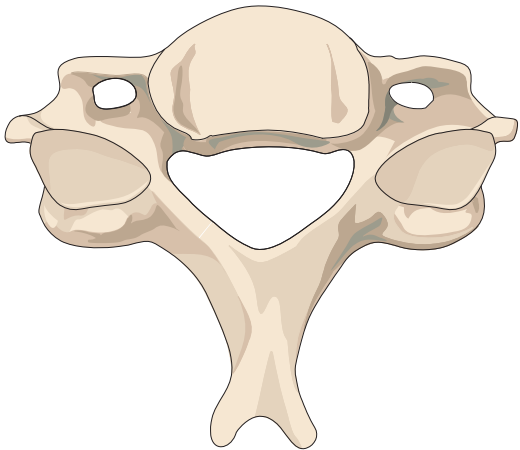
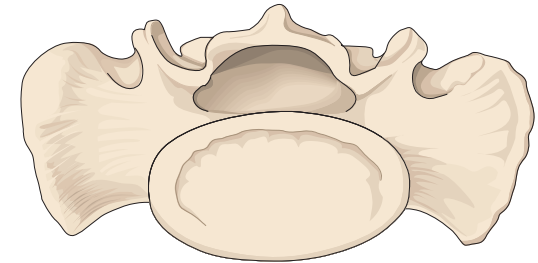
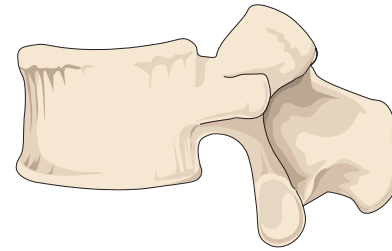
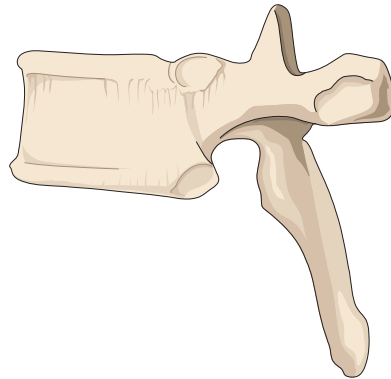
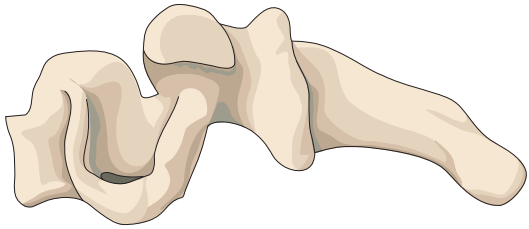




ANATOMÍA ESQUELÉTICA U ÓSEA DEL CUERPO: REGIÓN DE LA ESPINA DORSAL: PARTE 3



**VÉRTEBRAS:
Cervicales**

**VÉRTEBRAS:
Torácicas**

**VÉRTEBRAS:
Lumbares**

**VÉRTEBRAS:
Sacrales y
Coccígeas**